

# Prevention in Oral Implantology

Dov M. Almog, DMD, Craniofacial Digital Imaging (CDI), Adjunct Clinical Assoc. Prof.,  
Dept of Oral Diagnostic Sciences, Univ. of Buffalo, School of Dental Medicine.

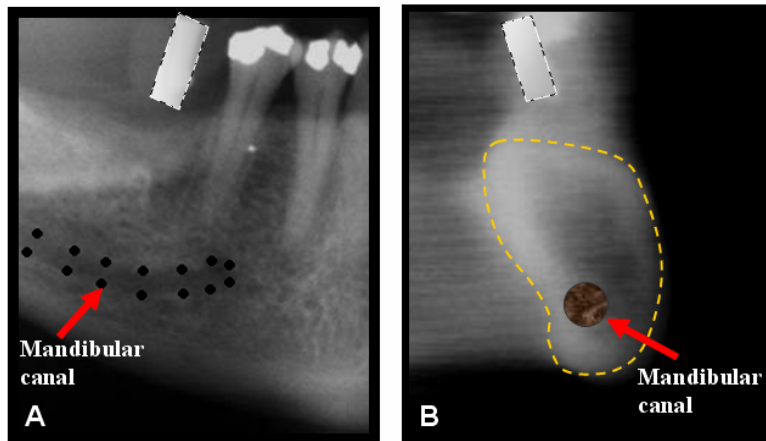
## Introduction

The objective of this paper is to provide a strong argument in favor of the call for action for the development of national guidelines for the use of CT-image-based systems based on restorative principles in the pre-operative assessment and treatment of dental implant cases.<sup>(1)</sup>

In a recent dental implant market analysis from Kalorama Information,<sup>(2)</sup> one of the fastest growing segments and most important developments in modern dentistry has been permanent tooth replacement with dental implants.

According to the Kalorama report, it is estimated that the growth in dental implant reconstruction products will outperform all other areas of dental devices and products. As dental implants become an increasingly viable treatment option for replacing single and or multiple missing teeth, we are bound to encounter more random anatomic conditions, necessitating complementary diagnostic imaging and surgical guidance solutions. Furthermore, as a result of this growth, there is an exponential increase in the number of practitioners involved in implant surgery, some experienced and others inexperienced.<sup>(2)</sup>

As a result of the quick adoption of oral implantology by the profession, new imaging modalities have evolved rapidly, with Cone-Beam CT's leading within the dental industry. This imaging technology provides 3D and cross-sectional views of the jaws in any user-defined plane.<sup>(3)</sup> Nevertheless, even the early imaging concepts served well the notion of prevention in oral implantology (figure 1), delineating optimal prosthetic trajectory, special relationship to anatomical landmarks and residual bone volume and trajectory.



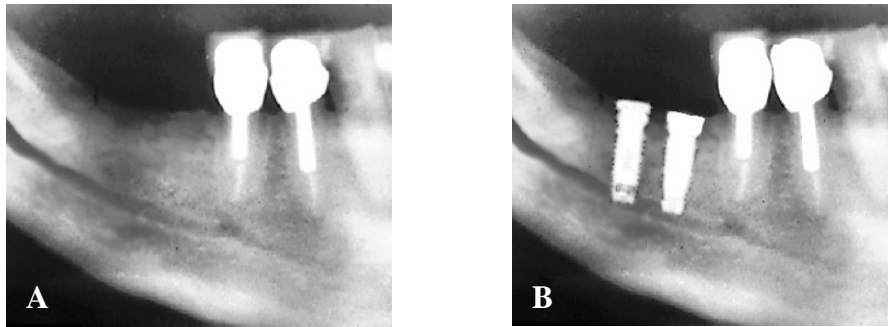
**Figure 1:** Early tomograms (panoramic view A and cross-sectional view B). Note a gutta percha imaging guide delineating the planned prosthetic trajectory of the 1<sup>st</sup> molar. Also note the assessable relationship to the mandibular canal, residual bone trajectory.

Although not scientific in nature, the argument in this paper is based on actual alarming clinical evidence presented in recent years.

## Case Reports

**Case #1:** The following case represents an undesirable incident involving an adult woman who was treated with dental implants in her lower jaw (figure 2).

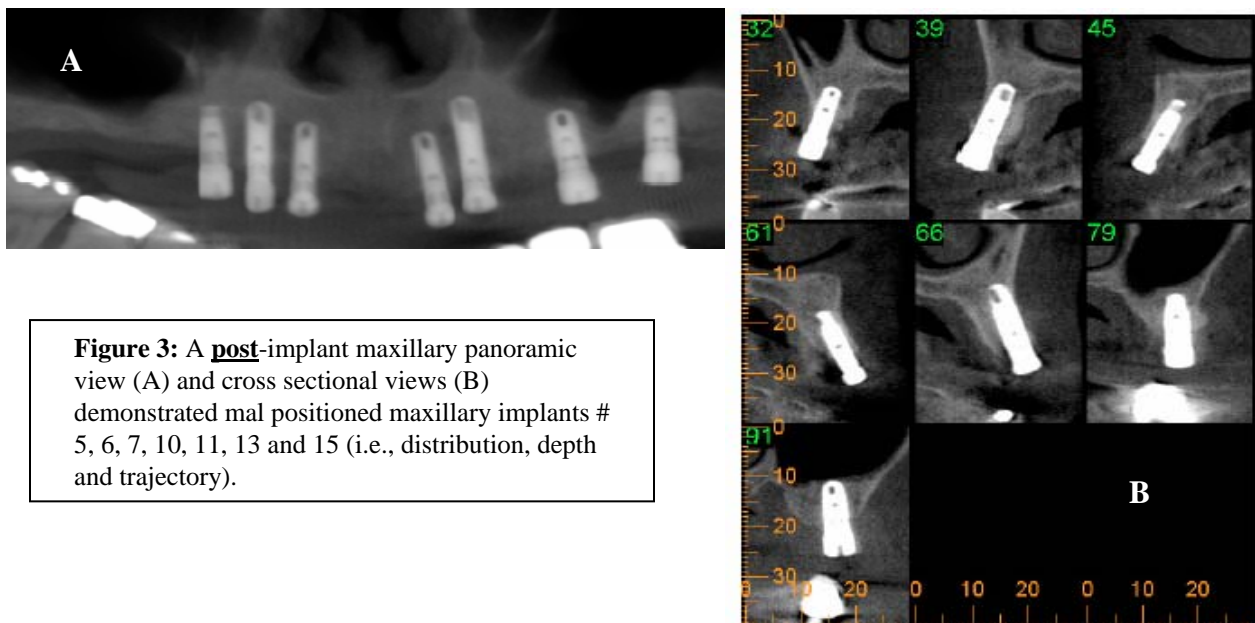
Did the patient receive inappropriate diagnostic care or diagnosis that falls below accepted norms? Should Cone Beam CT-imaging serve as an essential diagnostic tool in the pre-operative assessment and planning of such implants cases?



**Figure 2:** While a pre-operative panoramic view (A) is considered a pre-operative diagnostic study, magnification rate varies throughout the image and should **not** be used for precise measurements, especially surrounding critical anatomical landmarks. Nonetheless, the post-op x-ray (B) reveals alarming post-op invasion of the mandibular canal, resulting in an adverse outcome of permanent paresthesia of the subject's right lower jaw and lip.

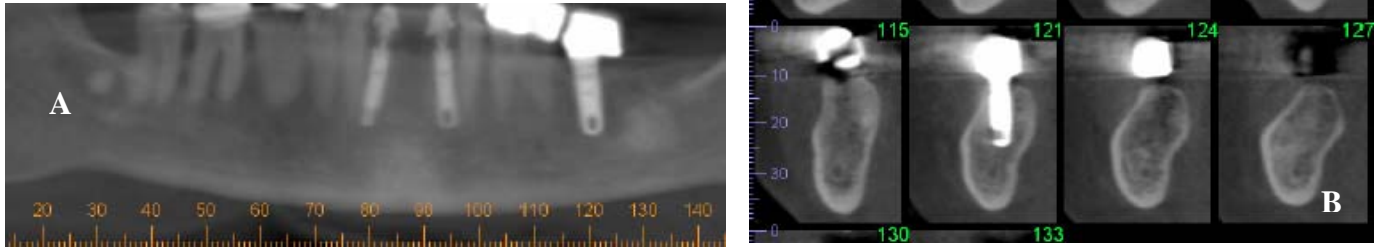
**Case #2:** The following case represents an undesirable outcome involving another adult woman who was treated with dental implants in both her upper and lower jaws. Implants were placed arbitrarily based on a panoramic radiograph and clinical examination. Consequently, lack of **pre**-implant restorative planning, presented a very challenging **post**-implant cosmetic rehabilitation case management (figures 3-6).

A **post**-implant CT study, performed using the i-CAT™ Cone Beam CT imaging technology (Imaging Sciences International, Hatfield, PA), demonstrated inconsistency with optimal restorative planning as far as implants distribution, trajectory and depth.

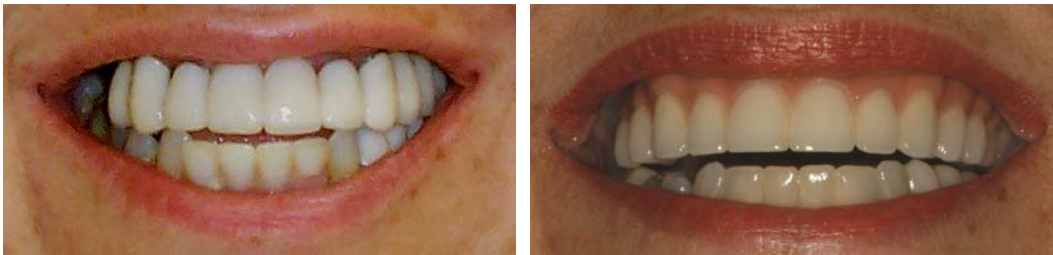

**Figure 3:** A **post**-implant maxillary panoramic view (A) and cross sectional views (B) demonstrated mal positioned maxillary implants # 5, 6, 7, 10, 11, 13 and 15 (i.e., distribution, depth and trajectory).

**Figure 4:** A post-implant panoramic view (A) and cross sectional views (B) of the mandible demonstrated mal positioned mandibular implants #23 and 26 (i.e., depth and trajectory).



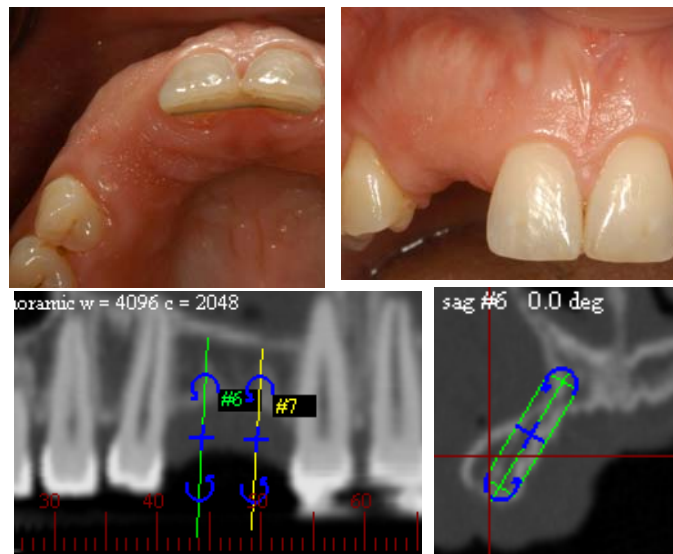
Consequently, following multiple visits, the patient's implant supported fixed restorations were remade, this time utilizing Atlantis abutments (Atlantis Components, Cambridge, MA), and reconstruction of her original gummy smile with pink porcelain (Figure 5).



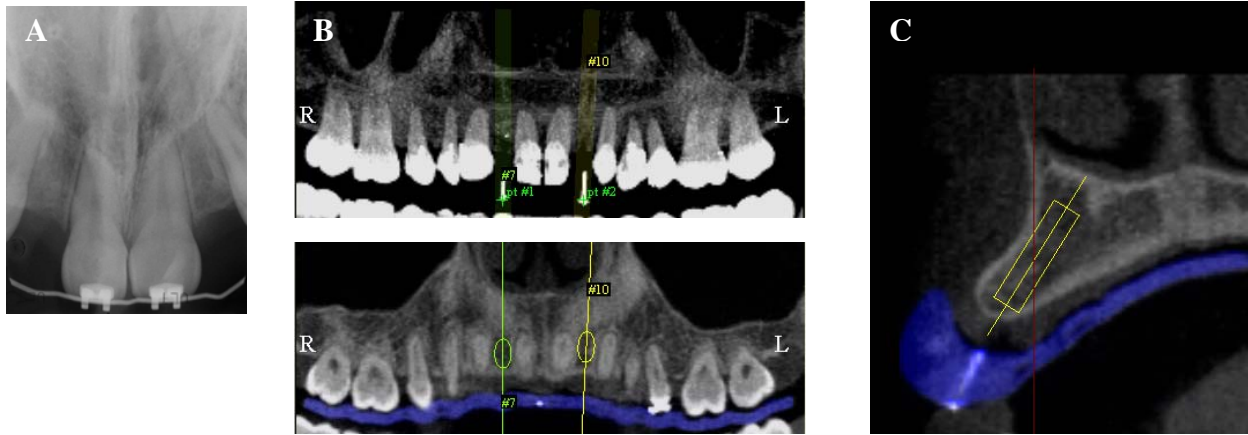
**Figure 5:** A before (A) and after (B) clinical images reveal profound restorative differences.

**Case #3:** The following case represents an individual who lost teeth #6 & 7 and was staged for treatment with dental implants. Clinical evaluation alone could have been very deceiving, suggesting ample of bone volume. Only a pre-op Cone-Beam CT revealed the bone deficiency at the apical region of said teeth (figure 6).

**Figure 6:** A Cone-Beam CT reveals severe narrowing of the apical region of the bone where teeth #6 & 7 used to be, necessitating preliminary bone grafting, followed by dental implants at a later stage.

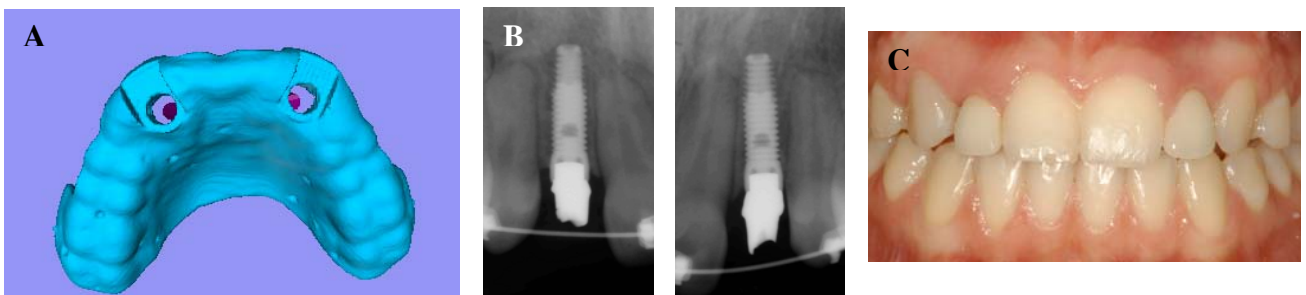


**Case #4:** The following case represents a young woman who presented with congenitally missing maxillary laterals and was treated with dental implants supported crowns. Pre-op orthodontic treatment was recommended in order to create space for implants #7&10 (figure 7A). About six months into the treatment a Cone-Beam CT study was conducted in order to ascertain optimal spacing (figure 7B&C).



**Figure 7:** Pre-op periapical radiograph of teeth 37&10 (A). Cone-Beam CT, both panoramic (B) and cross sectional (C) studies were used in conjunction with an imaging guide with radiopaque pins, representing optimal restorative trajectory.

The use of Cone-Beam CT imaging in conjunction with an imaging guide with radiopaque pins, allowed for optimal surgical-prosthetic planning as far as implants trajectory and size. Utilizing ImplantMaster™ (I-Dent, Ltd. Hod Hasharon, Israel), a 3-D reconstruction of the subject's anatomy was achieved and a surgical guidance template was designed and computer manufactured with precise drilling holes at the precise drilling trajectory (figure 8A). Metal guiding sleeves were assembled in the drilling holes; this gave the template rigidity in the drilling zone.



**Figure 8:** Utilizing the 3-D reconstructed surgical guidance template (A) was used to precisely and safely place the implants between the natural teeth (B), allowing for optimal restorative trajectories and ultimately resulting in an esthetically pleasing outcome (C).

## **Discussion**

In the first two cases discussed in this paper, there were no **pre**-implant studies done for evaluation of the surgical sights in relation to restorative objectives. Among other diagnostic purposes, CT imaging studies serve well the discipline of oral implantology. This diagnostic imaging modality was definitely indicated in these situations.

Furthermore, the Cone-Beam CT technology emerged as an optimal diagnostic tool for dentistry and at much less radiation to the patient, as some have claimed was taking place with medical CT's. Dental imaging dose comparison is provided in Table 1,<sup>(3)</sup> demonstrating the Cone-Beam CT technology as a safe diagnostic technology.

■ <b>Daily background:</b>	<b>8 uSv</b>
■ <b>Panoramic:</b>	<b>10-15 uSv</b>
■ <b>i-CAT 10 second scan:</b>	<b>30-35 uSv</b>
■ <b>i-CAT 20 second scan:</b>	<b>60-70 uSv</b>
■ <b>i-CAT 40 second scan:</b>	<b>90-100 uSv</b>
■ <b>Full mouth series:</b>	<b>150-200 uSv</b>
■ <b>Medical CT</b>	<b>1200-3300 uSv</b>

**Table 1:** An average diagnostic i-CAT Cone-Beam CT for dental implants takes 20 seconds. Every person receives natural background dose of 2500 to 5000 microsieverts in a year from things such as cosmic rays, the earth's crust, and from within our bodies. A single chest X-ray provides a dose of about 70 microsieverts, and yet, a Full Mouth Series provides a dose of about 150-200 microsieverts.

Granted, the second case was a complex and esthetically challenging implant case to begin with, especially in-lieu of the patient's high lip-line. However, a **pre-op** diagnostic restorative phase, coupled with the fabrication of an imaging guide based on prosthetic guidelines, followed by a Cone-Beam CT study, would have been proven to be extremely beneficial to all the parties involved.

## Conclusions

While there are no established standards regarding **pre**-implant restorative planning and CT-imaging as of yet, there is sufficient evidence around the country that this pre-implant diagnostic protocol makes dental implants more predictable and consequently safer and satisfying to the patients. Therefore, it is incumbent upon us to use this protocol in every dental implant case, and to use my colleague's phrase "surely this is a situation where an ounce of prevention is worth a pound of cure."<sup>(3)</sup>

1. Almog DM, Benson BW, Wolfgang L, Frederiksen NL, Brooks SL. CT-Based Imaging and Surgical Guidance in Oral Implantology. J Oral Implantol. 2006;32(1):14-8.
2. Kalorama Information, A Division of MarketResearch.com, September 2005, <http://www.kaloramainformation.com/pub/1099235.htm>.
3. White SC. An Ounce of Prevention. <http://apwdentalservices.com/news/APWOct2004.pdf>.